



Imaging Redefined

VITAL IMAGING Newsletter

Imaging Redefined

Imaging Redefined

3D CT IMAGING IN ORTHOPAEDICS

Volume 4: Issue 1

STATE OF THE ART 3D CT IMAGING IN ORTHOPAEDICS

Multislice Spiral CT (MSCT) is an excellent imaging modality for the evaluation of musculoskeletal (MSK) system, especially when coupled with **3D** volume rendering (**VRT**), **SSD** (Surface Shaded Display) & **MIP** (Maximum Intensity Projection) techniques & can change management in a lot of patients especially in cases of trauma.

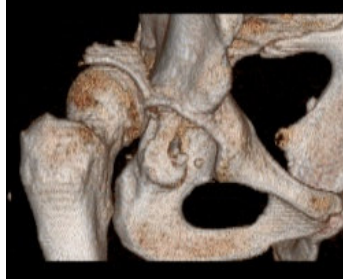INDICATIONS:

- Trauma
- Infection
- Tumours
- Post-operative Imaging
- Paediatric Applications etc.

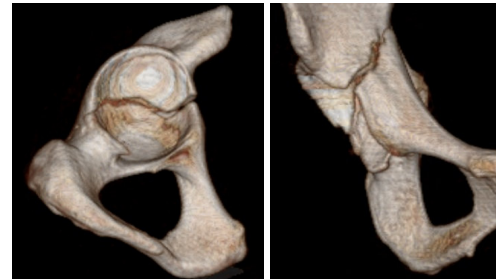
TRAUMA:

Role of 3D CT:

- > To confirm a fracture equivocal on x-rays.
- > Determine the extent & involvement of a previously diagnosed fracture thereby changing the management.



Fracture dislocation of acetabulum with intraarticular bone fragments.

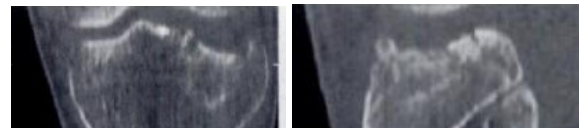
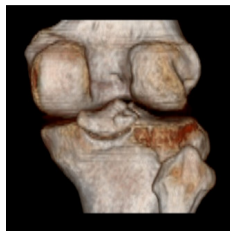

Non-displaced transverse fracture of acetabulum

PELVIS: 3DCT with VRT allows visualization of the entire pelvis through any plane or perspective. Any inlet or tangential view desired may be created, thus eliminating the need for time-consuming radiographic series. The volume data may be edited to isolate the fracture, & in select cases the femur may be disarticulated from the acetabulum. Concurrent sacral and sacroiliac injuries may also be identified.

VITAL IMAGING in ORTHOPAEDICS provides

- Digital X-Ray
- Dynamic High Resolution Musculoskeletal USG
- High Resolution Multislice CT
- 3D CT
- Colour Doppler
- Digital OPG
- Portable Digital X-Ray
- Portable Colour Doppler
- 24 x 7

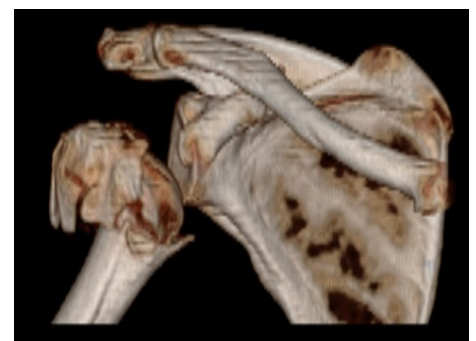


Tibial plateau fracture

KNEE: Multiplanar Reconstruction (MPR) & 3D VRT is ideal for evaluating acutely traumatized knee, even if the joint is in a partial cast. The reconstructed images can be used to identify and quantitate depression of the tibial plateau, even if the knee cannot be easily positioned as required for routine x-rays.

SHOULDER:

CT is extremely sensitive in the detection of three & four part fractures & 3D CT images can display the spatial relationship of the fracture fragments in this complex anatomic region, in particular, the number of fracture fragments & their degree of rotation which are critical factors in determining whether a proximal humeral fracture should be managed surgically.



Multipart fracture head of humerus

VITAL IMAGING CENTRE

B - Royal Classic, New Link Road, Next to Fame Adlabs, Andheri - West, Mumbai - 53.

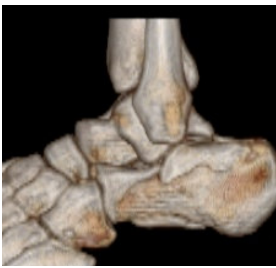Ph: 2630 1184 / 85

Email: info@vitalradiology.com

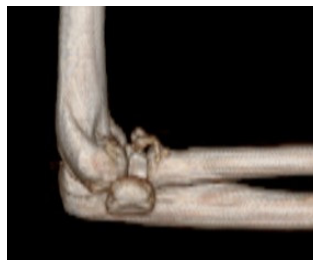Website: www.vitalradiology.com

Routine: - 8:30AM - 8:30PM

Emergency: - 24 x 7



Fracture Calcaneum



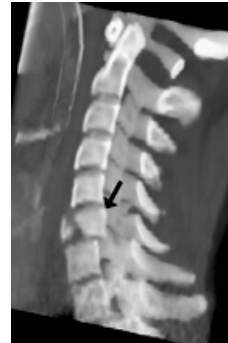Complex fracture Elbow

SPINE: For identification of fractures, subluxation, locked facets, localization of fracture fragments & foreign bodies. MSCT scan is also useful in evaluation of subtle sacral fractures missed on x-rays & in demonstrating its relationship to the sacral foramina.

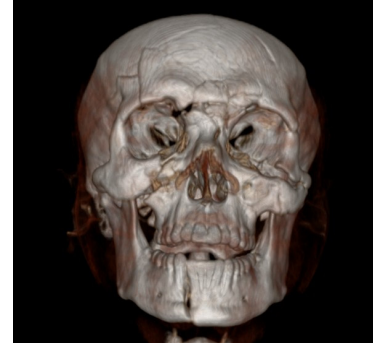
FACE: 3D CT is a front-line tool in identification of complex mandibular, maxillary & orbital fractures, assessing their extent & further management.

ANKLE: In complex intra-articular fractures of the distal tibia, talus or calcaneum, 3D CT can help the clinician in taking a decision as to go for immediate surgery or later definitive arthroplasty.

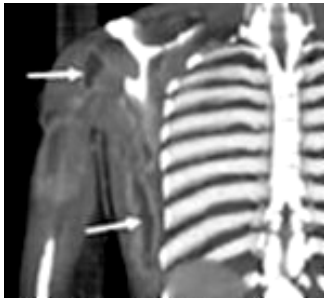ELBOW & WRIST: In equivocal cases and complex injuries.



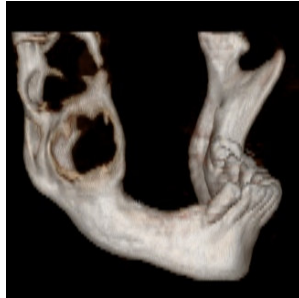Flexion tear drop fracture of C6 vertebra with posterior displacement of body.



Complex fracture of the mandible, maxilla & floor of orbit.



Multiple abscesses in the Rt arm & chest wall

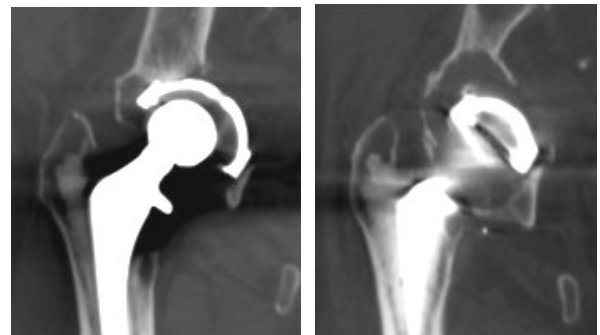

Ameloblastoma Mandible

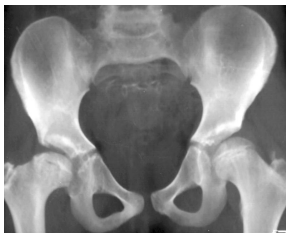INFECTION: MSCT with VRT is valuable in detecting cellulitis, necrotising fasciitis, pyomyositis, abscess, osteomyelitis, etc and to determine its extent & the compartments involved so as to decide medical vs surgical treatment

TUMOURS: MSCT is superior to MRI in detection of cortical destruction & lesion calcification MSCT with VR is especially valuable in anatomically complex areas such as pelvis, spine, shoulder, scapula etc

POST OPERATIVE IMAGING: When X-rays fail to answer a clinical question in post-operative patient, cross sectional imaging can help in further evaluation. MSCT with VRT can eliminate most streak artifacts, is the preferred modality & can produce high quality images on which the relationship between hardware, bones and bone fragments are well demonstrated. Callus formation in fractures can also be distinctively evaluated.



MIPR of Rt hip showing deficient medial acetabular wall with migration of the femoral head & a floating cup in the osteolytic zone posteriorly.



Dysplastic RT Hip with shallow acetabulum & flattened RT femoral head

PAEDIATRIC APPLICATIONS: Specific designs and care dose protocols can be used with MSCT to minimize radiation dosage to paediatric patients. Principal clinical application being developmental abnormalities, trauma, neoplasm and post-operative imaging.

CONCLUSION: 3DCT imaging is a fast, non-invasive & accurate technique for diagnosis, pre-operative evaluation as well as post-operative assessment of a large number of musculoskeletal diseases. With improved technology in MSCT it has now become an integral part of MSK imaging.

For Private Circulation Only.

For more information, or for any questions, concerns or suggestions please do call us on **Ph: 26301184 / 85.**

VITAL IMAGING > EXCELLENCE IN IMAGING... ALWAYS!