

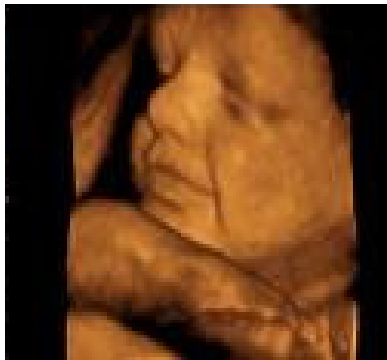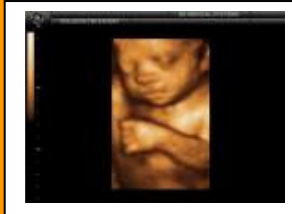## **The Sound Of Babies... 3D - 4D ULTRASOUND!**

**Excellence in  
ULTRASOUND  
@ VITAL**

*Prenatal diagnosis of fetal abnormalities has become one of the most important aspects of maternal fetal medicine.*

*Patients and referring physicians heavily rely on correct diagnosis of potential congenital abnormalities.*

**REAL TIME  
4D USG  
IS  
LIVE ACTION  
3D!**

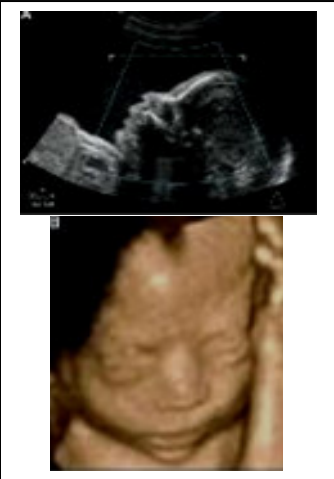

**3D / 4D USG has revolutionized the field of imaging with its ability to use multiple planes in which the area of interest can be displayed.**

**Advantages:**

- Accurate diagnosis about fetal abnormalities
- Improved understanding of fetal anatomy by parents
- Improved maternal fetal bonding.

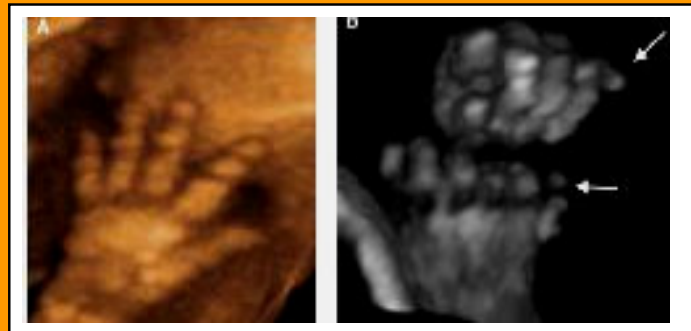
The importance of reassurance provided by 3D/4D USG in the absence of any fetal abnormalities is a blessing in disguise especially in high-risk families



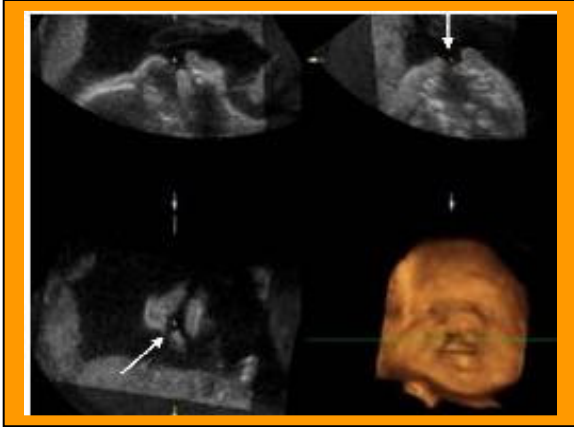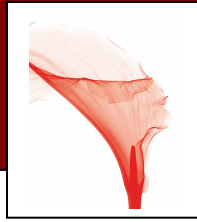
### **VITAL PREGNANCY SONOGRAPHY PACKAGES**

- DATING SCAN at 6 – 8 wks
- FIRST TRIMESTER at 11 – 14 wks SCREENING
- ANOMALY SCAN at 18 - 20 wks
- 3D / 4D SCAN at 18 - 20 wks
- 3D / 4D SCAN at 28 - 34 wks
- COLOUR DOPPLER at 30 - 40 wks

**3D images are helpful in assessing motion of the ankles, opening & closing of the mouth, movement of the arms & legs & counting digits of the hands.**



Pg: 1

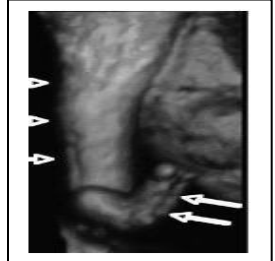

- **Cleft Lip & Palate** is one of the most common congenital abnormality & is highly associated with other congenital abnormalities
  - 3D / 4D USG is a useful tool in **correct identification & determination of the extent** of facial clefting
  - **Accuracy** of diagnosis of facial clefting is higher using 3D US in comparison with 2D USG
- A clear view of a fetal face with anomalies has a tremendous role in **making decisions** regarding **continuation of pregnancy, bonding, & conceptualization of the postnatal surgical care of the newborn***

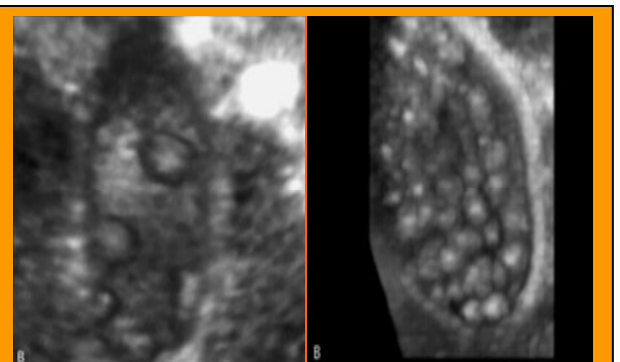
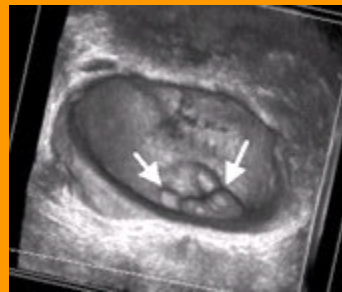**3D / 4D APPLICATIONS  
IN ABDOMEN:**

- Bladder – Masses, Polyps, Diverticula, Calculi.
- Prostate - BPH
- Vessels – Dissection, Plaques
- Gall bladder – Mass, Calculi, sludge
- Stomach – Rugal folds, masses
- Volumes of liver masses, gallbladder, or gallstones.
- Cysts & Collections

3-D is particularly helpful in evaluation for **Club Foot**, both because the ankle can be displayed & evaluated in a standard orientation & movement of the ankle can be assessed using 4-D



**Urinary Bladder  
Masses**



**GB Polyps**

**GB Stones**

**Pg: 2**

**VITAL IMAGING CENTRE**  
B-103, ROYAL CLASSIC, NEW LINK ROAD,  
ANDHERI WEST, MUMBAI – 53. **PH: 26301184 / 85**  
[www.vitalradiology.com](http://www.vitalradiology.com)

**(For Private Circulation Only)**  
For more information, questions or  
Suggestions Please call us on **26301184 / 85**  
Or email us at [newsletter@vitalradiology.com](mailto:newsletter@vitalradiology.com)

**MULTI SLICE CT SCAN**  
**MULTI SLICE SONOGRAPHY**  
**3D / 4D SONOGRAPHY**  
**COLOR DOPPLER**

**DIGITAL X-RAY**  
**DIGITAL OPG**  
**2D ECHO**  
**STRESS TEST**

**PATHOLOGY**  
**ECG / PFT**  
**PORTABLE USG/XRAY**  
**HEALTH CHECK UPS**

**24 x 7**  
**VITAL MOBILE IMAGING!**

**Ph: 26301184 / 85**